

Small Bowel Obstruction due to Meckel's Diverticulitis Presenting in Pregnancy

Abstract:

Meckel's diverticulitis is an extremely rare cause of acute abdomen during pregnancy. Depending on the clinical presentation it can be managed either by laparoscopy or laparotomy.

We report the case of a 29-year-old pregnant female, presenting with abdominal pain and distension in early second trimester. Abdominal Ultrasound scan was inconclusive. Magnetic resonance imaging showed small bowel obstruction with a dilated ileal loop. An inflamed Meckel's diverticulum adherent to the fundus of the gravid uterus was identified during laparotomy. Excision of Meckel's Diverticulum was carried out with a stapling device.

The diagnosis of Meckel's diverticulitis can be challenging, especially in pregnancy, and a delay in diagnosis can be detrimental to the mother and foetus. Although laparoscopic management has been reported to be safe in the second trimester, in this case the abdominal distension would have made access challenging and unsafe, and hence the decision to perform a laparotomy was taken.

Key words;

Meckel's diverticulitis; pregnancy; small bowel obstruction

Background:

Constipation is the common cause of abdominal pain and distention in pregnancy. If the symptoms do not settle there should be a high index of suspicion for more complex disorders. We report an extremely rare case of Meckel's diverticulitis presenting with small bowel obstruction in a 14-week pregnant woman.

The incidence of acute abdomen in pregnancy is rare (approximately 1 in 500 – 635 patients).¹ Appendicitis is the most common non-obstetric pathology (0.05 – 0.13%

Chaitra N Khanna¹, Paul R Harris¹, Gemma Faulkner¹

¹Department of General Surgery, Royal Bolton NHS Foundation Trust, Bolton, UK

chaitrank@icloud.com

Cite as: Khanna, C.N., Harris, P.R. & Faulkner, G. (2021) Small bowel obstruction due to Meckel's diverticulitis presenting in pregnancy. *The Physician* vol 7; Issue 1: 1-4 ePub 28.02.2021 DOI <https://doi.org/10.38192/1.7.1.5>

Article Information

Submitted 25.02.2021

ePub 28.02.2021

Revised 6.6.21



ISSN 2732-513X (Print)

ISSN 2732 - 5148 (Online)

cases of acute abdomen in pregnancy), followed by small bowel obstruction, sigmoid volvulus, intussusception (1 in 1500 – 1 in 3000), biliary disease and pancreatitis (1 in 5000).²

Case presentation

A 29-year-old Caucasian female, Gravida 2 and para 1 (previous normal vaginal delivery), presented at 14 weeks’ gestation with a 10-day history of colicky abdominal pain, abdominal distension and constipation. The patient was assessed by the obstetric team and managed conservatively with analgesia and laxatives. However, the symptoms failed to settle, and the patient developed vomiting, worsening abdominal distension and absolute constipation.

On admission the patient had stable blood pressure and was afebrile but was tachycardic

and tachypneic. On examination, her abdomen was distended, disproportionate to a 14-week pregnancy. There was right iliac fossa tenderness without peritonism. Foetal viability was monitored.

Investigations

The initial blood tests were normal; however, repeat blood tests the following day showed a raised white cell count and C-reactive protein (15.4 x 10⁹ per litre of blood, and 27.3 respectively). Ultrasound scan of the abdomen and pelvis was normal. Magnetic resonance imaging (MRI) showed small bowel obstruction, with the distal ileum dilated to 50 mm. There was no identifiable transition point. The appendix was normal with some free fluid noted in the pelvis (Figure 1).

Figure 1: Coronal section of Magnetic resonance imaging of the abdomen and pelvis.

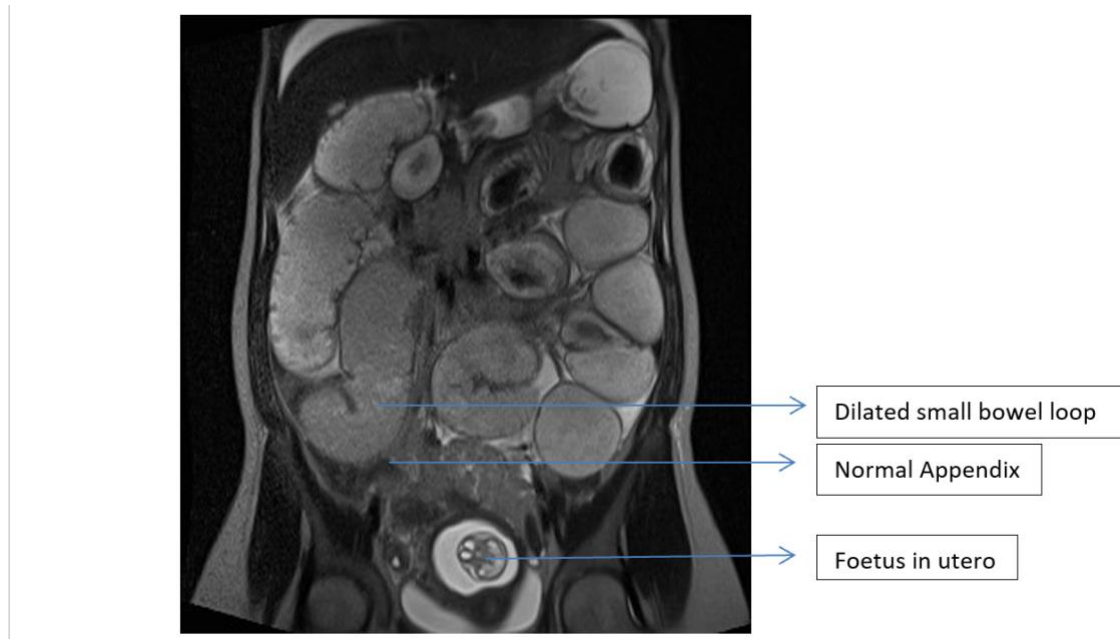


Figure 1: Coronal section of Magnetic resonance imaging of the abdomen and pelvis.

Management

The decision was taken to proceed to a laparotomy. A laparoscopic approach was not possible due to abdominal distension, which made access difficult and unsafe.

An inflamed Meckel's diverticulum causing small bowel obstruction was found at laparotomy

(Figure 2). The diverticulum was adherent to the fundus of the pregnant uterus. The small bowel was mobilised, and the Meckel's diverticulum was resected with a 60 mm transverse Linear Cutter stapler. The staple line was over sewn with 3-0 Polydioxanone suture.

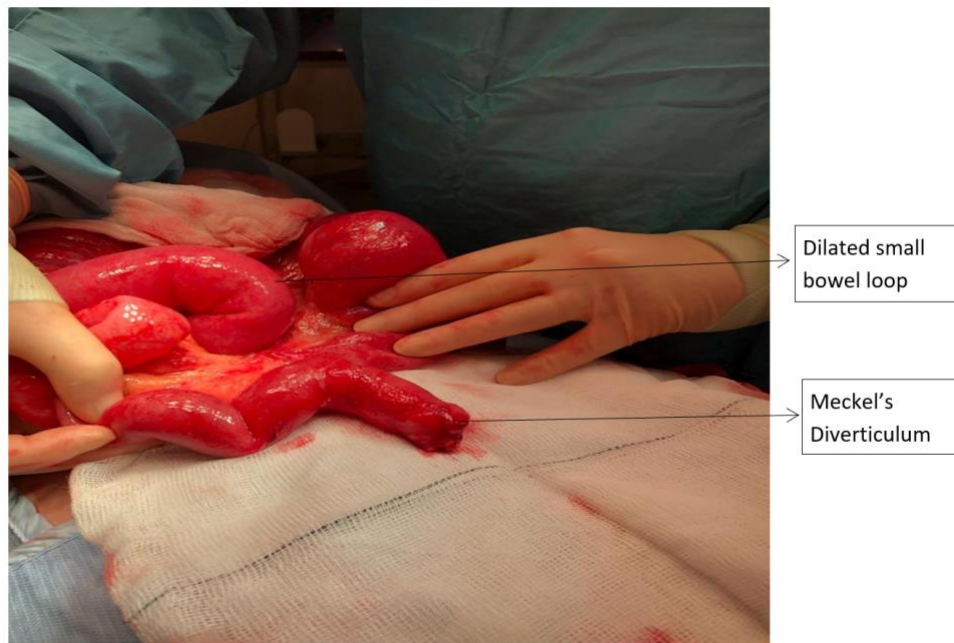

Figure 2: Intra-operative picture showing Meckel's diverticulum.

Post-operatively the patient recovered well and was discharged home two days later. Foetal heart monitoring was normal throughout the admission. Unfortunately, at two weeks following surgery the patient experienced a spontaneous miscarriage. No additional cause for this was identified. The histology was consistent with clinical diagnosis of an inflamed Meckel's diverticulum.

Discussion

The evaluation of an acute abdomen in a pregnant patient can be challenging due to ongoing physiological and anatomical changes. Abdominal symptoms such as nausea, vomiting and distension may get attributed to hormonal changes. Abdominal examination can be difficult due to the presence of a gravid uterus, which displaces the intra-abdominal organs. Early involvement of the surgeons by the obstetric team would be crucial in such cases, who fail to settle with conservative management.

Meckel's diverticulum is described as a true diverticulum present on the anti-mesenteric border of the terminal portion of ileum. It represents the persistence of the proximal part of the congenital vitellointestinal duct which usually obliterates during the fifth to seventh week of pregnancy. Johann Friedrich Meckel established the embryonic origin in 1809. Meckel's diverticulum is usually diagnosed in the paediatric population and is usually asymptomatic in adults.³

The lifetime risk of complications in association with a Meckel's diverticulum is approximately 4%. The most common complication in the adult population is small bowel obstruction. Haemorrhage is common in children.⁴

Meckel's diverticulitis as a complication of pregnancy is very rare. A review of world literature has shown only 26 case reports.⁵⁻⁷ Of the 26 cases, 4 presented with small bowel obstruction. A Computer Tomography (CT) scan is generally diagnostic ; however this is not advisable in pregnancy due to the high radiation dose.

Symptomatic Meckel's diverticulitis requires surgical management, which includes laparoscopic management. Laparoscopy has the dual advantage of being diagnostic, as well as a route for definitive treatment. A recent meta-analysis has shown an increased rate of miscarriages than a laparotomy however, comparable preterm birth rate.⁸ It is important that patients are counseled about the risks and benefits of laparoscopic procedures and surgery in general during pregnancy.

Conclusion

The diagnosis of small bowel obstruction secondary to Meckel's diverticulitis in pregnancy requires a high index of suspicion and prompt involvement of general surgical team to reduce harm to the mother and the foetus.

References:

1. Barber-Millet S, Lledó JB, Castro PG, Gavara IG, Pla NB, Domínguez RG. Update on the management of non-obstetric acute abdomen in pregnant patients. *Cir Esp* 2016; **94**: 257-65.
2. Pandeva I, Kumar S, Alvi A, Nosib H. Meckel's diverticulitis as a cause of an acute abdomen in the second trimester of pregnancy: laparoscopic management. *Case Rep Obstet Gynecol* 2015; **2015**:835609.
3. Sagar J, Kumar V, Shah DK. Meckel's diverticulum: a systematic review. *JR Soc Med* 2006; **99**:501–505.
4. Dumper J, Mackenzie S, Mitchell P, Sutherland F, Quan ML, Mew D. Complications of Meckel's diverticula in adults. *Can J Surg* 2006; **49**:353–357.
5. Huerta S, Barleben A, Peck MA, Gordon IL. Meckel's diverticulitis: a rare etiology of an acute abdomen during pregnancy. *Curr Surg* 2006; **63**:290-3.
6. Rudloff U, Jobanputra S, Smith-Levitin M, Kessler E. Meckel's diverticulum complicating pregnancy. *Arch Gynecol Obst* 2005; **271**:89–93.
7. Wong YS, Liu SY, Ng SS, Wong VW, Mak OS, Li JC et al. Giant Meckel's diverticulitis: a rare condition complicating pregnancy. *Am J Surg* 2010; **200**:184-5.
8. Juhasz-Böss I, Solomayer E, Strik M, Raspé C. Abdominal surgery in pregnancy—an interdisciplinary challenge. *Dtsch Arztebl Int* 2014; **111**:465–72.

Disclosure statement: Consent for medical illustration and publication obtained from patient. None of the authors have any conflicts of interest to declare and all authors have made a contribution towards the generation of this manuscript.