

# Implications of Axillary Lymphadenopathy Following COVID-19 Vaccination for Breast Cancer Screening

## **Abstract:**

**Aim:** We conducted a systematic review to study cases of women who reported abnormalities on mammograms following COVID-19 vaccination to evaluate the proportion of cases that warranted further investigations to rule out breast cancer. The review aimed to evaluate the need for further follow-up radiological investigations such as sonography etc. before invasive investigations were carried out to rule out breast malignancy.

**Methods:** Electronic Databases of PubMed, and Medline were searched on 18th July 2022, to extract published articles with the keywords: COVID-19 vaccination, Lymphadenopathy, and Mammogram. The publication timeframe of the included studies ranged from November 01, 2019, to July 18, 2022. Studies that were published in languages other than English were not considered for this systematic review. In vitro studies, In vivo studies, review articles and short communications were not considered for this systematic review. However, references of reviews were cross-checked for relevant publications.

**Results:** We identified 20 published results, and 9 publications were selected after eliminating reviews, communication articles, and non-research articles 1048 patients were included in the systematic review. with 287 patients reporting significant abnormalities on mammography findings, which would warrant further invasive investigations according to NHS, and UK protocols <sup>[9]</sup>

**Keywords:** Radiology, Mammogram, Axillary Lymphadenopathy, COVID-19, vaccination

Saad Jamal<sup>1</sup>, Vivek Pingali<sup>2</sup>,  
Mir Umar Farooq<sup>1</sup>  
*1 East Kent University Hospital, UK*  
*2 Rajarajeshwari Medical College & Hospital, Bengaluru, India*

[Saad.gx@gmail.com](mailto:Saad.gx@gmail.com)

Cite as: Jamal, S., Pingali, V., Farooq, M.U. (2023) Implications of axillary lymphadenopathy following COVID-19 vaccination for breast cancer screening. *The Physician* vol 8; Issue 3: Art 2 DOI 10.38192/1.8.3.2

## Article Information

Submitted 22.9.23

Revised 4.10.23

Published 27.10.23



**Introduction:**

**Coronavirus disease 2019 (COVID-19)** is a contagious viral disease caused by SARS-CoV-2. The first case was identified in Wuhan, China, in December 2019<sup>[1]</sup>. The symptoms of COVID-19 range from headache, fever, fatigue, cough, breathing difficulties etc. In severe cases, COVID-19 can lead to respiratory failure, shock, and multi-organ dysfunction.

COVID-19 has taken a massive toll on the health of the general population. To date, there have been 557,917,904 confirmed cases of COVID-19, including 6,358,899 deaths, reported to WHO<sup>[2]</sup>. To combat the increase in COVID-19 cases and deaths, efforts were made worldwide to produce vaccines to decrease transmission and mortality. In 2020, the first COVID-19 vaccines were made available to the public through emergency approval and authorisation. In the UK, three vaccines are currently in use, which are the BNT162b2 vaccine, by Pfizer and BioNTech, the ChAdOx1 nCoV-19 (AZD1222) vaccine, by the University of Oxford and AstraZeneca, and the mRNA-1273 vaccine developed by Moderna. These vaccines were authorised for emergency use by the MHRA<sup>[3]</sup>

To date, more than 12 billion doses of COVID-19 vaccines have been administered worldwide, to combat the rising mortality due to the illness<sup>[4]</sup>. Much interest has been generated about the side effects due to COVID-19 vaccines. While minor side effects such as soreness, redness, rash, inflammation, fatigue, and headache are common, many of these are self-resolving.

Among the major side effects, a particular one of interest is that of axillary lymphadenopathy. Such vaccination-

associated reactive lymphadenopathy is considered a local adverse reaction to vaccination. As per Lam et al.<sup>[5]</sup>, when compared to other vaccines, reactive lymphadenopathy was more commonly observed following administration of COVID-19 mRNA vaccines. Although both protein-based vaccines and mRNA vaccines stimulate antigen-presenting cells to travel to regional lymph nodes and stimulate cell-mediated and humoral immunity, mRNA vaccines cause a more robust stimulation of the germinal centre of the lymph node and increased B cell proliferation, thereby causing reactive lymphadenopathy.

In a briefing document released by the United States Food Drug Administration<sup>[6]</sup> it was seen that 11.6% of beneficiaries of the Moderna vaccine reported ipsilateral axillary lymphadenopathy following the first dose, and 16% reported the same reaction following the second dose. In another study, among beneficiaries of the Pfizer-BioNTech vaccine, 64/21720 patients developed similar complaints lasting 8-10 days<sup>[7]</sup>.

However, these cases of lymphadenopathy post-COVID-19 vaccination have caused concern when manifesting as lumps in the breast or axilla being confused as a sign of breast malignancy. These can be a cause for worry among women performing breast self-examinations, or even when they are spotted on routine mammograms. In an article published in the American Journal of Roentgenology, of 23 women with COVID-19 vaccine-related adenopathy follow-up recommendations of further imaging or biopsy were required in all but one patient<sup>[8]</sup>. In such cases, which are likely to yield a false positive result, this can lead to a strain on the healthcare system, by creating an unnecessary need for further investigations. Along with this,

if a mass is found by a General Practitioner in the NHS, UK,(National Health Service-United Kingdom) the patient is likely to be referred to a specialist breast cancer clinic where the patient will likely be subjected to a triple assessment, which would include invasive investigations such as either a fine needle aspiration for cytology (FNAC) or a biopsy of the mass<sup>[9]</sup>, causing unnecessary discomfort to patients. As per the National Institute for Clinical Excellence UK – patients who are 30 years or older and have a lump in their armpit that their GP doesn't think is caused by anything else, may be offered an appointment to see a cancer specialist to check for breast cancer within 2 weeks- commonly referred to as the 2 weeks wait referral pathway.[21]

In this systematic review, we sought to understand the number of women who have developed COVID-19-related axillary lymphadenopathy and evaluate the proportion of these women who would have been subjected to further investigations.

We sought to recommend further follow-up imaging after a specified time interval before the patient is subjected to invasive diagnostic tests.

NICE UK states the following about the 2-week referral pathway for cancer diagnosis:

Refer people using a suspected cancer pathway referral for breast cancer if they are:

- a) aged 30 and over and have an unexplained breast lump with or without pain or
- b) aged 50 and over with any of the following symptoms in one nipple only:
  - discharge
  - retraction
  - other changes of concern.

Consider a suspected cancer pathway referral for breast cancer in people:

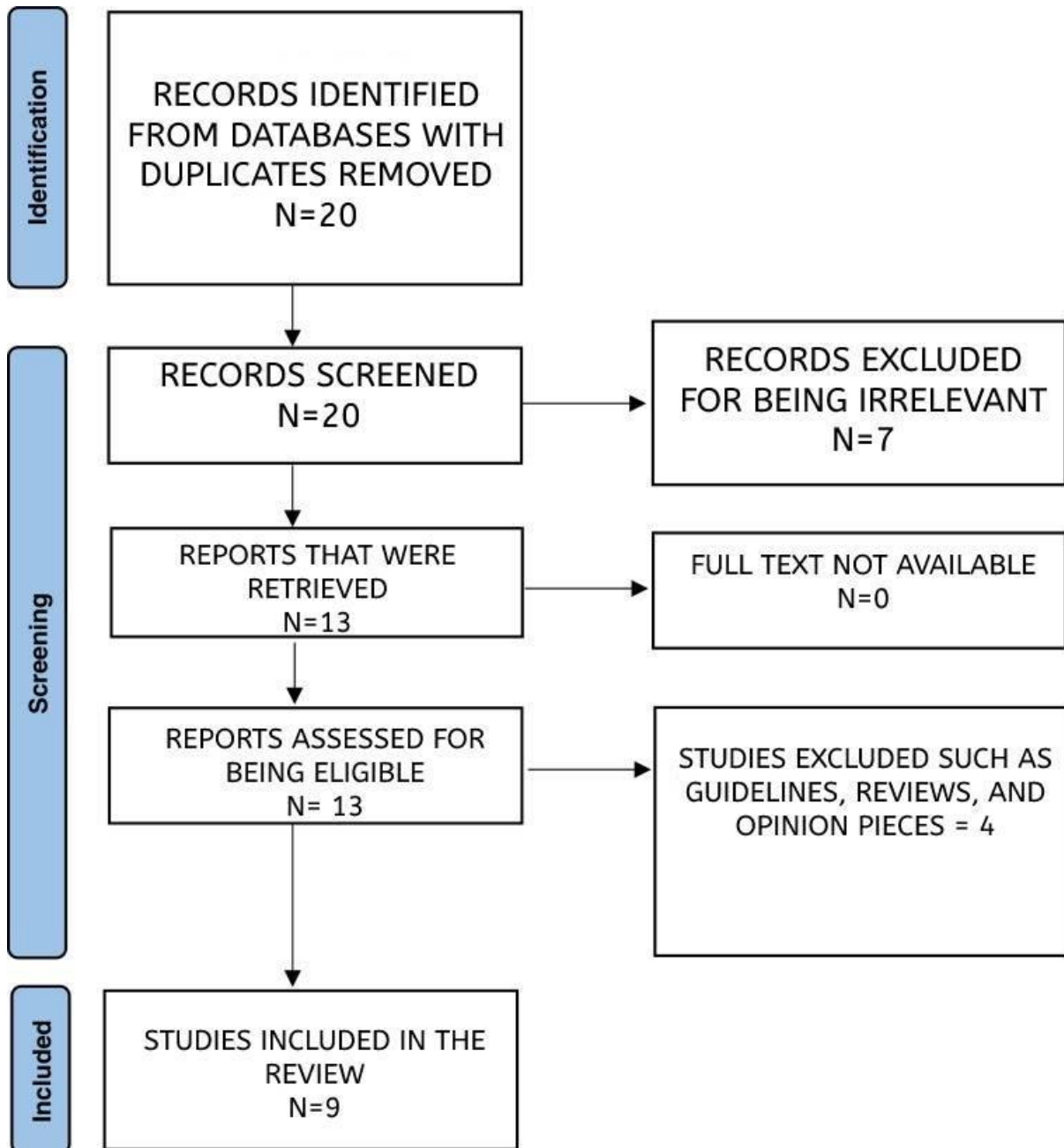
- a) with skin changes that suggest breast cancer or
- b) aged 30 and over with an unexplained lump in the axilla.

Consider non-urgent referrals in people aged under 30 with an unexplained breast lump with or without pain.

Measures put in place to rule out lymphadenopathy post-COVID-19 vaccination may help avoid referring patients for investigations such as sonographic studies, aspiration, and biopsies, as well as help to conserve resources by seeking to avoid the 2 week-wait referral pathways, as well as reduce the number of non-urgent referrals.

## Methodology:

The data was collected according to the PRISMA statement, and board approval was not required since this was a systematic review.



Data Collection: We searched the electronic databases of PubMed, and Medline using the keywords “COVID-19 vaccination, Lymphadenopathy, Mammogram” which yielded 20 results. These results were screened by the authors

and duplicates were eliminated from contention.

Inclusion criteria: We included all articles published in the English Language, from November 01, 2019, to July 18, 2022.

Exclusion Criteria: The abstracts of the resulting articles were screened by the authors and studies that were not published in English, in vitro studies, in vivo studies, review articles, short communications, and opinion pieces were not considered for this systematic review. From the resulting 13 publications, the full-text articles were screened, and those

which were not relevant were screened out, resulting in 9 publications.

## Results

The following were the studies chosen for the systematic review.

Name of the study	Author	Number of women who were diagnosed with COVID-19-related lymphadenopathy	Detected via	Vaccine	Time between vaccination and development of lymphadenopathy	Age Range	Inclusion/Exclusion Criteria
COVID-19 Vaccination Induced Lymphadenopathy in a Specialized Breast Imaging Clinic in Israel: Analysis of 163 cases <sup>[10]</sup>	Faermann Et al.	119/153 cases of lymphadenopathy were attributed due to the vaccine.	Ultrasound, MRI, Mammography	Pfizer-BioNTech COVID-19 Vaccine	-		The study population included all women who underwent breast imaging during the study period who presented newly detected unilateral axillary lymphadenopathy on imaging, and had a history of recent COVID-19 vaccination to the ipsilateral arm
Adenopathy Following COVID-19 Vaccination <sup>[11]</sup>	Washington et al.	1 (Case Report)	Mammogram, Sonography	Moderna COVID-19 vaccine (mRNA-1273)	5 days	37-Year-Old	-
COVID-19 Vaccination-Associated Axillary Adenopathy: Imaging Findings and Follow-Up Recommendations in 23 Women <sup>[12]</sup>	Shabnam Mortazavi	23	Self-Exam, Mammography, USG, MRI	-	Median Interval = 9.5 days (2-29 days)	49+/-21 years	For MRI, a node was considered abnormal when asymmetric in size and/or number in comparison with nodes in the contralateral axilla.

Unilateral axillary lymphadenopathy following COVID-19 vaccination: A case report and imaging findings <sup>[13]</sup>	Dominguez et al.	1 (Case Report)	CT, Mammogram, Ultrasound	Pfizer COVID-19 vaccination	3 days	38 Year old	
Incidence of Axillary Adenopathy in Breast Imaging After COVID-19 Vaccination <sup>[14]</sup>	Robinson et al.	23/750 Patients	Mammography Additional USG was requested for 17 patients	-	Median time = 10-18 days	median [range] 64 [35-83] vs 67 [31-94]	Received at least 1 injection of COVID-19 vaccine fewer than 90 days prior to either screening or diagnostic mammography
Time for Resolution of COVID-19 Vaccine-Related Lymphadenopathy and Associated Factors <sup>[15]</sup>	Glance et al.	111 patients with ipsilateral Adenopathy, following COVID vaccination	Breast Ultrasound	Pfizer or Moderna COVID-19 vaccine	<8 weeks	Mean age: 52+/- 12 years	Patients with unilateral axillary lymphadenopathy ipsilateral to mRNA COVID-19 vaccine administration performed within the prior 8 weeks that was detected on breast ultrasound performed between January 1, 2021, and October 1, 2021, and who underwent follow-up ultrasound examinations at 4- to 12-week intervals until resolution of the lymphadenopathy  Cortical thickness of the largest axillary lymph node on ultrasound was retrospectively measured and was considered enlarged when greater than 3 mm.
Transient ipsilateral breast edema following COVID-	Lim et al.	1 (Case report)	Screening Mammogram	Moderna COVID-19 vaccine	2 days	60 Year Old	-

19 vaccination <sup>[16]</sup>	al.		raphy				
Mammographic and sonographic findings in the breast and axillary tail following a COVID-19 vaccine <sup>[17]</sup>	N Locklin et al.	3 (Case Report)	Screening Mammography	-	1-11 days	83 year old, 36 year old, 60 Year old	-
Mammographic findings of diffuse axillary tail trabecular thickening following immunization with mRNA COVID-19 vaccines: Case series study <sup>[18]</sup>	Adam et al.	5 (Case Series)	Screening Mammography	Pfizer or Moderna COVID-19 vaccine	Within 1 week	-	-

**Follow Up Studies:**

Name of the study	Author	Follow up:
COVID-19 Vaccination Induced Lymphadenopathy in a Specialized Breast Imaging Clinic in Israel: Analysis of 163 cases <sup>[10]</sup>	Faermann Et al.	
Adenopathy Following COVID-19 Vaccination <sup>[11]</sup>	Washington et al.	2-week follow up US: No change in Lymphadenopathy.  -Planned for 3-month Follow up US
COVID-19 Vaccination-Associated	Shabnam Mortazavi	Mentions Mehta et al. recommended follow-up of the affected axilla 4–12 weeks after

<p>Axillary Adenopathy: Imaging Findings and Follow-Up Recommendations in 23 Women<sup>[12]</sup></p>		<p>the second dose with targeted ultrasound to evaluate for resolution</p>
<p>Unilateral axillary lymphadenopathy following COVID-19 vaccination: A case report and imaging findings<sup>[13]</sup></p>	<p>Dominguez et al.</p>	<p>Follow-up axillary ultrasound done 4 days later showing multiple mildly enlarged lymph nodes with cortical thickness upto 0.5cm</p>
<p>Incidence of Axillary Adenopathy in Breast Imaging After COVID-19 Vaccination<sup>[14]</sup></p>	<p>Robinson et al.</p>	<p>no follow-up (n = 2), repeated ultrasonography with or without mammogram in 3 months (n = 14), and biopsy (n = 1).</p>
<p>Time for Resolution of COVID-19 Vaccine-Related Lymphadenopathy and Associated Factors<sup>[15]</sup></p>	<p>G Lane et al.</p>	<p>Lymphadenopathy resolution: 97 ± 44 days after the initial ultrasound examination, 127 ± 43 days after the first vaccine dose</p>
<p>Transient ipsilateral breast edema following COVID-19 vaccination<sup>[16]</sup></p>	<p>L Mcgrath et al.</p>	<p>Recommended short-term follow-up at 6-8 weeks</p>
<p>Mammographic and sonographic findings in the breast and axillary tail following a COVID-19 vaccine<sup>[17]</sup></p>	<p>N Locklin et al.</p>	<p>n=1 follow up within 4 weeks Showed complete resolution of changes</p>



<p>Mammographic findings of diffuse axillary tail trabecular thickening following immunization with mRNA COVID-19 vaccines: Case series study<sup>[18]</sup></p>	<p>Adam et al.</p>	<p>n=1 follow up mammography 7 weeks later showed complete resolution of changes</p> <p>n=1 follow up mammography 1 month later showed resolution of changes</p> <p>n=2 follow up mammography 6 weeks later showed complete resolution of changes</p> <p>n=1 follow up mammography 5 weeks later showed complete resolution of changes</p>
--	--------------------	--

From the above studies, lymphadenopathy following COVID-19 vaccination is not an uncommon occurrence. In the study conducted among cases of lymphadenopathy following COVID-19 vaccination by Faermann et al., 119/153 (77%)<sup>[10]</sup> cases were attributed to the COVID-19 vaccine. Furthermore, an incidence of 23/750 (3%)<sup>[14]</sup>, of axillary lymphadenopathy following COVID-19 vaccination was reported by Robinson et al. Along with this, the remaining 7 publications studied a total of 145 women who demonstrated axillary lymphadenopathy, either as a presenting symptom or following screening breast imaging following COVID-19 vaccination.

It is also evident from the studies that all the patients had received at least one dose of either the Pfizer-BioNTech COVID-19 vaccine or the Moderna COVID-19 vaccine (mRNA-1273). The time duration between vaccine administration and reporting of axillary lymphadenopathy varied from 1 day to ~8 weeks. There is also a very wide age range from the above

studies with the youngest patient being 31, and the oldest patient being 94 years old.

## Discussion

Axillary lymphadenopathy following COVID-19 vaccination is not an uncommon occurrence as seen in healthcare settings around the globe. As described by Faermann et al., 78% of women developed axillary lymphadenopathy following COVID-19 vaccination,<sup>[10]</sup> and the rest due to other causes such as metastatic cancer, or reactive lymphadenopathies. Furthermore, in a study conducted by Wolfson et al.,<sup>[19]</sup> out of 1217 patients who received the COVID-19 vaccination, 537 patients were reported to have axillary lymphadenopathy in at least one breast imaging examination (44%). 46% of the People who received the Moderna vaccine among the 1217 patients developed lymphadenopathy, and 38% of the patients who received the Pfizer Vaccine

developed lymphadenopathy. Ruling out COVID-19 vaccine-associated lymphadenopathy before referral for further investigations to rule out malignancy would save resources and time, especially in patients above 30 years.

The occurrence of lymphadenopathy following COVID-19 vaccination can raise worries, especially in the presence of screening programs such as the Breast Cancer Screening Program by the NHS, which routinely screens women every 3 years from the ages of 50-71.<sup>[20]</sup> Given that this age group of the population is prioritised for COVID-19 vaccination, the development of COVID-19 vaccine-associated lymphadenopathy can be confused for a warning sign for breast cancer and can lead to an increased number of referrals to specialised breast clinics, creating longer waiting times for patients and placing a larger load on healthcare in a country.

Furthermore, such axillary lymphadenopathy, if identified during a mammogram screening, or a visit to the GP, is likely to warrant further investigation at a specialised breast clinic such as the triple assessment, which involves physical examination, further imaging, and invasive tests such as a biopsy or FNAC of the lymph node.<sup>[9]</sup> This would subject patients to an array of invasive tests that are likely to cause discomfort.

Patients would likely benefit from additional screening at a later follow-up date rather than postponing mammography screening if they have a recent history of COVID-19 vaccination. Such follow-up examinations could either be a repeat mammogram or sonography. The studies show that the appearance of lymphadenopathy can be anywhere

between 1 day to around 8 weeks following vaccination.

Further research, however, is needed to specify the time frame between detection of axillary lymphadenopathy post-COVID-19 vaccination and repeat follow-up imaging, by evaluating the time for resolution of COVID-19-associated lymphadenopathy. In the study conducted by G Lane et al.<sup>[15]</sup>, mentioned above, it can be seen that lymphadenopathy post-COVID-19 vaccination, lymphadenopathy resolved  $97 \pm 44$  days following the initial ultrasound, and  $127 \pm 43$  days following the first vaccine dose, a much longer duration than mentioned in initial vaccine trials. Therefore, given that the time for the lymphadenopathy to resolve takes a large amount of time, instead of delaying screening ultrasounds, it would be more beneficial for patients to undergo serial imaging to note the progress of the lymphadenopathy. Further research, on a larger scale, is however needed to establish guidelines to tackle this issue.

It is necessary to note that lymphadenopathy has many causes, and some of the most common causes to rule out are shortened by the acronym MIAMI (malignancy, infection, autoimmune disorder, miscellaneous, and iatrogenic). Clinical history taking and examination are key to ascertaining a provisional diagnosis, and it must be noted that not all cases of lymphadenopathy post-COVID-19 vaccination, are iatrogenic and further investigation must be carried out before ruling out more concerning differential diagnoses. Furthermore, a repeat follow-up sonographic study could also be arranged to evaluate the resolution of changes. The studies above by Adam et al., N Locklin et al. G Lane et al., all were able to evaluate a mean time frame for the resolution of changes, and it would be

worthwhile considering an upper limit for the time that the lymphadenopathy has persisted beyond which a repeat ultrasound/mammogram could be arranged. Risk factors for malignant causes of lymphadenopathy can include being greater than 40 years of age, male sex, Caucasians, supraclavicular and/or generalised lymphadenopathy, and systemic symptoms. [13]

The NHS also faces a recent increase in waiting lists for cancer diagnosis. Data collected from Cancer Research UK shows that all targets for 2-week wait referrals, faster diagnosis standard, 62-day standard and 31-day standards were missed as of July 2023[22]. The financial burden of investigating breast cancer also is a factor to be taken into consideration with the cost of the screening programme for the cohort of women followed for 35 years (£4.8m for each year screened). [23]

## Conclusion

It is important to recognise that a large proportion of patients develop COVID-19 vaccine-associated axillary lymphadenopathy which can last anywhere between 1-8 weeks. It would be important therefore to assess the history of COVID-19 vaccination while assessing patients presenting with axillary lymphadenopathy before considering a referral to Breast cancer diagnostic services. This may lead to a reduction in unnecessary referrals, and conserve valuable resources.

## References

1. Page J, Hinshaw D, McKay B (26 February 2021). "In Hunt for Covid-19 Origin, Patient Zero Points to

Second Wuhan Market – The man with the first confirmed infection of the new coronavirus told the WHO team that his parents had shopped there". *The Wall Street Journal*. Retrieved 27 February 2021.

2. WHO Coronavirus (COVID-19) Dashboard | WHO Coronavirus (COVID-19) Dashboard With Vaccination Data

3. COVID-19 vaccines | Vaccine Knowledge (ox.ac.uk)

4. Richie H, Ortiz-Ospina E, Beltekian D, Methieu E, Hasell J, Macdonald B, et al. (5 March 2020). "Coronavirus (COVID-19) Vaccinations – Statistics and Research". *Our World in Data*.

5. Axillary Lymphadenopathy After COVID-19 Vaccination in a Woman With Breast Cancer | Breast Cancer | JAMA | JAMA Network

6. Moderna COVID-19 Vaccine: Vaccines and Related Biological Products Advisory Committee Meeting, December 17, 2020. Accessed September 28, 2021. <https://www.fda.gov/media/144434/download>

7. Polack FP, Thomas SJ, Kitchin N, et al; C4591001 Clinical Trial Group. Safety and efficacy of the BNT162b2 mRNA Covid-19 vaccine. *N Engl J Med*. 2020;383(27):2603-2615. doi:10.1056/NEJMoa2034577

8. COVID-19 Vaccination–Associated Axillary Adenopathy: Imaging Findings and Follow-Up Recommendations in 23 Women :

American Journal of Roentgenology : Vol. 217, No. 4 (AJR) (ajronline.org)

9. Breast cancer in women - Diagnosis - NHS (www.nhs.uk)

10. COVID-19 Vaccination Induced Lymphadenopathy in a Specialized Breast Imaging Clinic in Israel: Analysis of 163 cases - PubMed (nih.gov)

11. Adenopathy Following COVID-19 Vaccination - PubMed (nih.gov)

12. COVID-19 Vaccination-Associated Axillary Adenopathy: Imaging Findings and Follow-Up Recommendations in 23 Women - PubMed (nih.gov)

13. Unilateral axillary lymphadenopathy following COVID-19 vaccination: A case report and imaging findings - PubMed (nih.gov)

14. Incidence of Axillary Adenopathy in Breast Imaging After COVID-19 Vaccination - PubMed (nih.gov)

15. Time for Resolution of COVID-19 Vaccine-Related Lymphadenopathy and Associated Factors - PubMed (nih.gov)

16. Transient ipsilateral breast edema following COVID-19 vaccination - PubMed (nih.gov)

17. Mammographic and sonographic findings in the breast and axillary tail following a COVID-19 vaccine - PubMed (nih.gov)

18. Mammographic findings of diffuse axillary tail trabecular thickening following immunization with mRNA COVID-19 vaccines: Case series study - PubMed (nih.gov)

19. Axillary Adenopathy after COVID-19 Vaccine: No Reason to Delay Screening Mammogram | Radiology (rsna.org)

20. When you'll be invited for breast screening and who should go - NHS (www.nhs.uk)

21. <https://www.nice.org.uk/guidance/ng12/ifp/chapter/breasts-and-armpits#lumps-in-your-armpits>

22. Cancer waiting times: Latest updates and analysis (cancerresearchuk.org)

23. Cost effectiveness of the NHS breast screening programme: life table model | The BMJ