

CASE REPORT

INCREASED RISK OF VENOUS THROMBOEMBOLISM IN COVID-19

Mana Rahimzadeh MBBS ¹, Pakinee Pooprasert MBBS ²

1 St George's University Hospital, London

2 Maritime Hospital, Kent, UK

Abstract:

We report a case of a 61-year-old male who had recently been discharged home after contracting COVID-19 during an extended hospital admission. He presented to the emergency department after episode of sudden onset central chest pain and D-dimer was 390 mcg/L on admission. The patient was initially managed for acute coronary syndrome, however within twenty-four hours of admission the patient desaturated to 74% on room air and required 15L oxygen. CT Pulmonary Angiogram showed right lower lobe segmental pulmonary emboli and extensive COVID-19 lung changes. Subsequently, acute coronary syndrome treatment was stopped, and the patient treated for pulmonary embolus. Following this, his oxygen requirement improved significantly, and the patient stabilised within one week.

Emerging data and clinical evidence suggests an increased risk and prevalence of venous thromboembolic events in COVID-19, particularly in patients with more severe disease. It is currently unclear how long this increased risk persists. This case report highlights the importance of risk stratification of patients on discharge from hospital, to determine who requires extended thromboprophylaxis on discharge. Going forward, clinical trials are needed to evaluate the duration and dose of thromboprophylaxis in high-risk patients, and aid the formation of clearer guidelines for clinicians.

Background:

The novel coronavirus disease (COVID-19) has spread worldwide, infecting over 3 million people and causing over 230,000 deaths. Patients with COVID-19 may be at an increased risk of developing venous thromboembolic (VTE) diseases, as the infection is associated with increased inflammation, disseminated intravascular coagulation (DIC), hypoxaemia and immobility (1,2). The incidence of VTE in COVID-19 is not yet established. However emerging data suggests an increased risk and prevalence of venous thromboembolic events in COVID-19, particularly in patients with more severe disease (3). Klok et al. demonstrated 27% of 184 Dutch ICU patients had CTPA and/or ultrasonography confirmed VTE and 3.7% had arterial thrombotic events. All these patients received at least standard dose thromboprophylaxis (4). In a French study, Llitjos et al. systematically screened for VTE in anticoagulated COVID-19 patients using complex dual ultrasound (CDU). They found 69% of the 26 ICU patients with COVID-19 had VTE (5). Given the recent emergence of COVID-19, there is currently no longitudinal data assessing the prevalence of venous thromboembolic events in patients surviving COVID-19 infection.

Case Presentation:

A 61-year-old male presented to the emergency department (ED) after episode of sudden onset central chest pain, which woke him in the night. The patient reported this pain as heavy in nature and 10/10 in severity, with associated nausea. He denied any radiation or exacerbating factors.

Four days prior to ED admission, the patient had been discharged from a two-month hospital stay, during which he had been diagnosed with COVID-19 (36 days prior to this presentation) and required non-invasive ventilation in intensive care. He had been anticoagulated with prophylactic dose LMWH throughout this admission but was not put on anticoagulation therapy post discharge.

His pertinent past medical history includes end-stage renal failure requiring haemodialysis, previous myocardial infarctions with stenting to right coronary artery in 2018, adrenal insufficiency, hypertension and asthma with recurrent chest infections. He is an ex-smoker who gave up 20 years prior.

Upon review, the patient was alert, conscious and not in respiratory distress. His vital signs on presentation were as follows:

- Temperature: 37.3 degrees Celsius,
- Heart rate 84 beats per minute,
- Respiratory rate 18 breaths per minute,
- Blood pressure 162/99 mmHg
- Oxygen saturation 98% on room air.

Physical examination revealed bi-basal crepitations on auscultation and lower limb oedema to the mid-shin level, but no calf tenderness or erythema. Heart sounds were normal, and abdomen was soft and non-tender.

His electrocardiogram showed atrial flutter, with no new ischaemic changes. Troponin was 72 and 74 ng/mL when repeated 6 hours later, which in the context of end stage renal failure was difficult to interpret (Creatinine was 323 $\mu\text{mol/L}$, and eGFR was 17 mL/min/1.73m²). His white cells were in normal range and CRP was 62 mg/L. D-dimer was 390 mcg/L on admission.

Diagnosis:

Initially, the primary differential diagnosis was acute coronary syndrome (ACS). Other important differential diagnoses requiring exclusion included aortic dissection, pulmonary embolism, pneumothorax and pneumonia.

Initial Management and Prognosis:

CT Aortography showed no evidence of aortic dissection.

Chest X-Ray showed atelectasis in both bases but no focal consolidation.

Initially, the patient was managed as an ACS patient and was also commenced on unfractionated heparin infusion.

However, in light of lack of ischaemic changes on repeat ECGs and stable troponin levels, ACS became a less likely differential diagnosis.

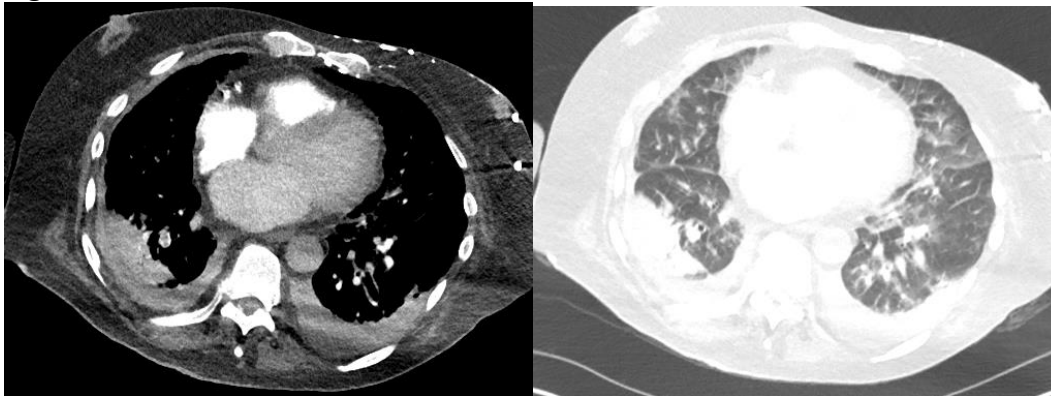
Case Progression and Outcome:

Within twenty-four hours of admission, the patient desaturated to 74% on room air and was requiring up to 15L oxygen to maintain target saturations. Type I respiratory failure was demonstrated on arterial blood gas (pO₂ 7.11 kPa with FiO₂ 0.35, pCO₂ 4.57).

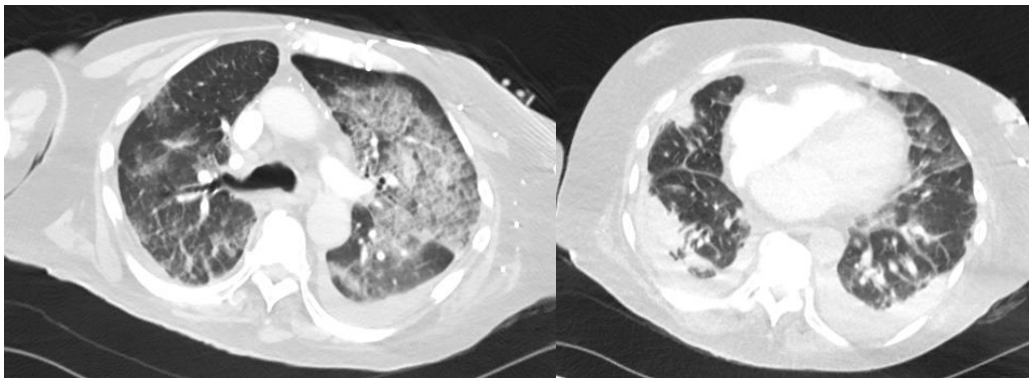
The patient was commenced on IV antibiotics to cover chest sepsis and an urgent CT Pulmonary Angiogram was arranged. Repeat bloods showed a significant rise in inflammatory markers (White Cell Count 12.3 10⁹/L, CRP 410mg/L).

The CT Pulmonary Angiogram (CTPA) showed right lower lobe segmental pulmonary emboli and extensive COVID-19 lung changes, with more focal areas of dense consolidation within the right lower lobe (Fig 1).

Fig 1:



- a) Axial CT, vascular sequence. Reports showed filling defect within right lower lobe segmental arteries in keeping with acute pulmonary embolus.
- b) Axial CT, lung sequence



- c) Axial CT, lung sequence. Extensive ground glass changes noted within both lungs, worse on the left.
- d) Axial CT, lung sequence. Reports highlight some more organised, focal dense consolidation seen at the right lower lobe.

ACS treatment was stopped, and the patient was loaded on unfractionated heparin and commenced on warfarin therapy to treat the pulmonary embolus. During admission, his oxygen requirement improved significantly, and he made good clinical progress. Within five days of admission, he was no longer requiring oxygen and was mobilising short distances.

Discussion:

Emerging data suggests an increased risk and prevalence of venous thromboembolic events in COVID-19, particularly in patients with more severe disease. Using a nationwide Chinese dataset, Wang et al. show that 40% (407) of the 1026 patients that were included were considered as high risk for VTE with a score of 4 or more on the Padua Prediction Score(6). However, they show that 11% of these 407 patients also had a high risk of bleeding(3). Thus, risk stratification must balance the risk of VTE with the risk of bleeding.

Whilst there are currently no clear national guidelines, the British Thoracic Society guidance on VTE has stated that on discharge, extended thromboprophylaxis can be considered if the patient is at a high risk of VTE, such as past history of VTE, cancer, significantly reduced mobility or a critical care admission (7). They suggest that while the nature and duration of thromboprophylaxis is unclear, a standard approach of prophylactic dose of low molecular weight heparin (LMWH) or direct oral anti-coagulant for four weeks might be considered as appropriate.

This case demonstrates the importance of developing clearer risk stratification for COVID-19 patients who would benefit extended thromboprophylaxis after hospital discharge. To our knowledge, there is currently no evidence in the literature studying excess risk of VTE post COVID-19. Going forward, clinical trials evaluating the dose and duration of LMWH thromboprophylaxis in patients with COVID-19 are critically required to aid risk stratification and clinical management.

Learning Points:

- Recognising increased risk of acute venous thromboembolism in patients who have had recent COVID-19 infection
- Risk stratification of patients on discharge from hospital with COVID-19 in order to determine who requires extended thromboprophylaxis
- A requirement for more data assessing the prevalence of venous thromboembolic events in patients surviving COVID-19 infection
- A requirement for more trials to evaluate the duration and dose of thromboprophylaxis in high-risk patients to aid the formation of clearer guidelines for clinicians

References

1. Guan W-J, Ni Z-Y, Hu Y, Liang W-H, Ou C-Q, He J-X, et al. Clinical Characteristics of Coronavirus Disease 2019 in China. *N Engl J Med*. 2020 Apr;382(18):1708–20.
2. Zhou F, Yu T, Du R, Fan G, Liu Y, Liu Z, et al. Clinical course and risk factors for mortality of adult inpatients with COVID-19 in Wuhan, China: a retrospective cohort study. *Lancet (London, England)*. 2020 Mar;395(10229):1054–62.
3. Wang T, Chen R, Liu C, Liang W, Guan W, Tang R, et al. Attention should be paid to venous thromboembolism prophylaxis in the management of COVID-19. *Lancet Haematol* [Internet]. 2020 May 1;7(5):e362–3. Available from: [https://doi.org/10.1016/S2352-3026\(20\)30109-5](https://doi.org/10.1016/S2352-3026(20)30109-5)
4. Klok FA, Kruip MJHA, van der Meer NJM, Arbous MS, Gommers DAMPJ, Kant KM, et al. Incidence of thrombotic complications in critically ill ICU patients with COVID-19. *Thromb Res* [Internet]. 2020 Apr 10 [cited 2020 May 3]; Available from: <https://www.sciencedirect.com/science/article/pii/S0049384820301201>
5. Llitjos J-F, Leclerc M, Chochois C, Monsallier J-M, Ramakers M, Auvray M, et al. High incidence of venous thromboembolic events in anticoagulated severe COVID-19 patients. *J Thromb Haemost*

-
- [Internet]. 2020; Available from: <http://www.ncbi.nlm.nih.gov/pubmed/32320517>
6. BARBAR S, NOVENTA F, ROSSETTO V, FERRARI A, BRANDOLIN B, PERLATI M, et al. A risk assessment model for the identification of hospitalized medical patients at risk for venous thromboembolism: the Padua Prediction Score. *J Thromb Haemost* [Internet]. 2010 Nov 1;8(11):2450–7. Available from: <https://doi.org/10.1111/j.1538-7836.2010.04044.x>
 7. British Thoracic Society. BTS Guidance on Venous Thromboembolic Disease in patients with COVID-19. *Br Thorac Soc* [Internet]. 2020;(April):1–5. Available from: <https://www.brit-thoracic.org.uk/document-library/quality-improvement/covid-19/bts-guidance-on-venous-thromboembolic-disease-in-patients-with-covid-19/>